

Video Article

A Novel Approach for the Administration of Medications and Fluids in Emergency Scenarios and Settings

Akilesh Honasoge¹, Neal Lyons², Kathleen Hesse³, Braden Parker³, Robert Mokszycki², Kelly Wesselhoff³, Rolla Sweis², Erik B. Kulstad³¹College of Medicine, University of Illinois at Chicago²Department of Pharmacy, Advocate Christ Medical Center³Department of Emergency Medicine, Advocate Christ Medical CenterCorrespondence to: Erik B. Kulstad at kulstad@uic.eduURL: <http://www.jove.com/video/54622>DOI: [doi:10.3791/54622](https://doi.org/10.3791/54622)

Keywords: Medicine, Issue 117, medication administration, proctoclysis, rectal absorption, fluid administration, pharmacokinetics, emergency medicine

Date Published: 11/9/2016

Citation: Honasoge, A., Lyons, N., Hesse, K., Parker, B., Mokszycki, R., Wesselhoff, K., Sweis, R., Kulstad, E.B. A Novel Approach for the Administration of Medications and Fluids in Emergency Scenarios and Settings. *J. Vis. Exp.* (117), e54622, doi:10.3791/54622 (2016).

Abstract

The available routes of administration commonly used for medications and fluids in the acute care setting are generally limited to oral, intravenous, or intraosseous routes, but in many patients, particularly in the emergency or critical care settings, these routes are often unavailable or time-consuming to access. A novel device is now available that offers an easy route for administration of medications or fluids via rectal mucosal absorption (also referred to as proctoclysis in the case of fluid administration and subsequent absorption). Although originally intended for the palliative care market, the utility of this device in the emergency setting has recently been described. Specifically, reports of patients being treated for dehydration, alcohol withdrawal, vomiting, fever, myocardial infarction, hyperthyroidism, and cardiac arrest have shown success with administration of a wide variety of medications or fluids (including water, aspirin, lorazepam, ondansetron, acetaminophen, methimazole, and bupirone). Device placement is straightforward, and based on the observation of expected effects from the medication administrations, absorption is rapid. The rapidity of absorption kinetics are further demonstrated in a recent report of the measurement of phenobarbital pharmacokinetics. We describe here the placement and use of this device, and demonstrate methods of pharmacokinetic measurements of medications administered by this method.

Video Link

The video component of this article can be found at <http://www.jove.com/video/54622/>

Introduction

The most common routes of administration for medications and fluids in the emergency care setting are generally oral (if the patient can tolerate oral intake), intravenous (for more rapid administration, or provision of medications not orally bioavailable), or intraosseous (in the case where intravascular access is difficult to obtain). Nevertheless, in many cases, patients who are too ill to tolerate oral intake are also dehydrated, with poor vascular access that prevents placement of intravascular (IV) lines. In most cases, intraosseous placement is not an ideal option, since the discomfort of administration in an awake patient can be significant.

A new device, the catheter, offers an alternative route via rectal mucosal absorption, which is a route long-known to be effective and easy to access¹⁻¹¹. Absorption through the rectal mucosa is generally rapid, with blood levels of many drugs attaining therapeutic levels rapidly, in part as a result of avoiding the first-pass effect.¹² The catheter has a silicone tube that is 14 Fr in diameter and has a 15 mL balloon at the tip. The balloon provides for secure retention of the catheter for retention of administered medications and fluids, yet also allows elimination through passage via defecation. The catheter has multiple exit ports at the distal tip for fluid and medication passage, and an internal one-way check valve at the proximal end to prevent backflow of fluids (**Figure 1**). A description of the components of the device is shown in **Table 1**.

This catheter, which became available in 2014, was originally intended for palliative care and hospice patients, being designed to meet the needs of family members taking care of patients in the home setting, eliminating the need for hospitalizations and more invasive care. The product design particularly enables the preservation of the patient dignity while being easy enough for those without a medical background to use. However, because of its appeal for use with emergency department and critical care patients, the device has been increasingly utilized in this setting recently. In particular, case reports and case series describing the novelty of this approach in the emergency setting first appeared just in the last year^{13,14}.

The features and benefits of the catheter enable easier and more efficient use of the rectal mucosal administration route than has been available previously. Placement of the catheter is easy, with no need for sterility. Use of the device requires no advanced training, since it is placed in a manner similar to a standard Foley catheter. Because placement is simple, repeat attempts at vascular access can be avoided, which increases satisfaction of both providers and patients. Indications for the device are to provide rectal access to administer liquids/medications.

Case Presentation

A number of examples of use of the catheter in emergency settings, including emergency departments and intensive care units, have been recently reported¹³⁻¹⁴. Examples of these include:

Case 1

An 80-year-old male with multiple medical comorbidities, including obesity, chronic leg wound, skin grafts, HTN, CAD, and COPD, presented to the Emergency Department (ED) via ambulance with fever, decreased mental status, and cough. Attempts at IV access by ambulance personnel, and subsequently by ED personnel after arrival, were unsuccessful. The patient's initial vital signs were: BP 124/68, HR 98, T 38.4 °C, O₂ saturation of 92% on 2L NC, and GCS of 14 (due to confusion).

Case 2

A 41-year-old female presented via ambulance in alcohol withdrawal with vital signs of BP 110/78, HR 120, T 36.9 °C, and oxygen saturation of 98% on room air. Her Clinical Institute Withdrawal Assessment of Alcohol (CIWA) score was 9. Attempts at obtaining IV access for administration of fluids and benzodiazepines were unsuccessful, and the patient was deemed too disoriented and agitated to safely tolerate oral administration.

Case 3

A 25-year-old female presented via ambulance with acute confusion, agitation, and tachycardia resulting from substance abuse, including cocaine and heroin. She had an underlying untreated hyperthyroidism for which the patient was previously taking methimazole. Her vital signs were BP 118/73, HR 117, T 37.4 °C, and oxygen saturation of 97% on room air. IV access was established with some difficulty; however, the patient remained too confused and agitated to safely tolerate methimazole tablets (the medication is only available in oral form).

Case 4

A 59-year-old male was brought into the ED after a cardiac arrest followed by return of spontaneous circulation after defibrillation, but persistent coma. Therapeutic hypothermia was instituted, but despite maximum cooling power provided by external surface pads, the patient's temperature was noted to be climbing, likely as a consequence of ongoing shivering. Because an NG tube placed to suction revealed gastric contents to be similar in appearance to coffee grounds, GI bleeding was suspected, and NG tube administration of medications, including acetaminophen and buspirone was felt to be contraindicated.

Diagnosis, Assessment, and Plan

In all of the above patients, this method of medication delivery provided a useful alternative treatment modality to address challenging medication and fluid administration conditions.

Protocol

1. Assessment Guidelines Prior to Placement

1. Prior to insertion, assess rectal opening for contraindications which include: lesions, tumors, abscesses, rectal bleeding, diarrhea or recent bowel surgery (less than 6 weeks).
2. Assess rectum for stool by performing a digital rectal exam prior to placement.
NOTE: It is best if the rectum is empty, however, formed stool in the rectum is not a contraindication for use.

2. Insertion of the Device

1. Lubricate catheter from the tip to the blue marker line with water-soluble lubricant.
2. Insert the catheter into the rectum to the blue marker line between the two blue arrows.
3. Inflate balloon with Luer syringe by injecting 15 mL water or saline.
4. Gently tug catheter to assure balloon is positioned against the rectal sphincter.
5. Position catheter between the legs and secure to the anterior aspect of the patient's thigh or lower abdomen with a catheter-securing device.

3. Medication Preparation and Administration

1. Pulverize solid forms of medications.
2. Add 10 - 20 mL water to pulverized medication to produce a microenema suspension.
3. Pull microenema suspension into enteral syringe and inject quickly into catheter port over about 3 - 5 sec.
NOTE: For medication already in liquid form, Step 3.1 and 3.2 are not necessary.
4. Quick-flush the Medication Administration Port (over less than one sec) with 3 mL of water using a 3 mL enteral syringe.

4. Hydration (Proctoclysis Procedure)

1. Administer hypotonic solutions only (water, 0.2% Normal Saline, 0.5% Normal Saline, etc.).
2. Administer bolus fluids using a large (45 or 60 mL) enteral syringe at a rate of about 60 mL over 15 - 30 sec.

NOTE: A hydration infusion via the catheter may be done using a gravity tube feeding bag which attaches readily to the medication port on the Macy Catheter. Infusion at rates of up to 250 - 400 mL/h have been shown to be well tolerated.⁷

5. Catheter Removal

1. Remove the catheter before defecation. The catheter can remain in the rectum for up to 28 days.
NOTE: The catheter is easily expelled with defecation and will not inhibit the passing of stool.
2. To remove the catheter deflate balloon with a Luer syringe. Attach 20 mL Luer syringe to balloon inflation valve and gently withdraw the 15 mL water from the balloon. Remove gently from the rectum.
NOTE: Contraindication for use. Do not use the catheter for patients with rectal lesions, tumors, active rectal bleeding or recent bowel surgery (less than 6 weeks). Do not use if rectal mucosa is compromised (ulcers or ischemic proctitis). Do not use for patients with diarrhea.

Representative Results

Initial reports of the use of this method of medication and fluid delivery in the emergency or critical care setting demonstrate rapid effects from the medications and fluids administered in the variety of conditions described^{13,14}. In addition, these patients tolerated the procedure well with no complaints of discomfort. The average time taken for placement of the catheter was about 1 min. Furthermore, the procedure was well accepted and the patients who were awake and alert verbalized satisfaction with this mode of fluids and medications delivery. The clinical outcomes for the four cases presented are shown below.

Clinical Outcomes

Case 1

The 80-year-old male with multiple medical comorbidities was provided a total of 50 mL of fluids and medications, including water, aspirin tablets dissolved in water, and acetaminophen (oral formulation), for the treatment of fever, dehydration, and elevated troponin. Approximately 90 min later, the patient was afebrile, alert, and oriented (**Figure 2**).

Case 2

The 41-year-old female in alcohol withdrawal and a Clinical Institute Withdrawal Assessment of Alcohol (CIWA) score of 9 was given 2 mg of lorazepam, resulting in immediate improvement of the patient's agitation, orientation, and tachycardia. The patient was then given 4 mg of ondansetron along with multiple aliquots of tap water at a rate of 10 mL every 2 - 10 min over the subsequent hour, resolving her tachycardia and eliminating her nausea, while bringing her CIWA score to zero.

Case 3

The 25-year-old female with acute confusion, agitation, and tachycardia resulting from substance abuse (cocaine and heroin) with an underlying untreated hyperthyroidism, was given methimazole tablets after being crushed and suspended in water. The catheter remained in place in the Intensive Care unit (ICU) for subsequent administrations every six hours until the patient improved sufficiently to begin tolerating oral intake the day after admission.

Case 4

The 59-year-old cardiac arrest patient was given liquid acetaminophen (650 mg) and Buspirone (30 mg) via the catheter, which was then flushed with normal tap water. Shortly after the administration of these medications, the patient's previously rising core temperature effectively plateaued at 36.9 °C and he clinically stopped shivering.

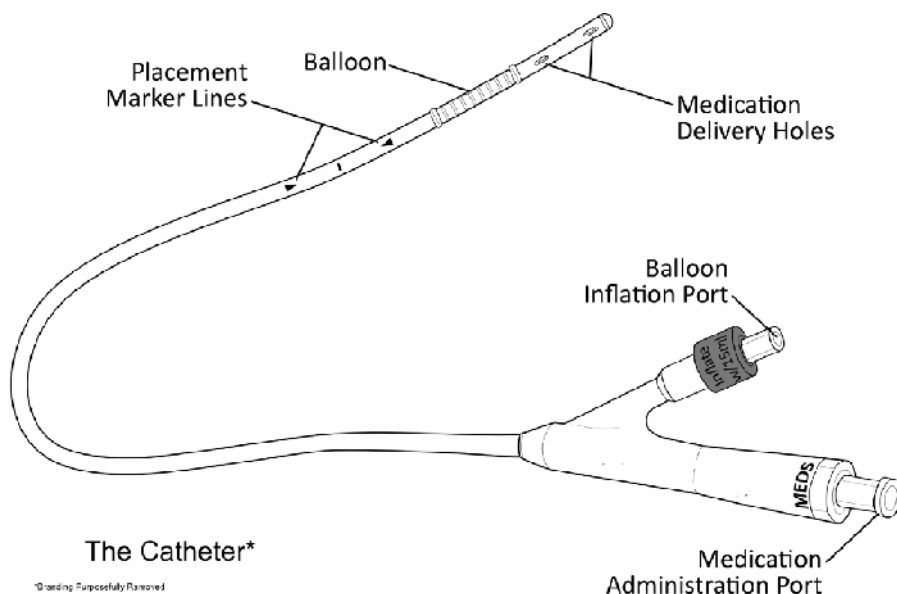


Figure 1. Diagram of Catheter. Reprint with permission from manufacturer. [Please click here to view a larger version of this figure.](#)

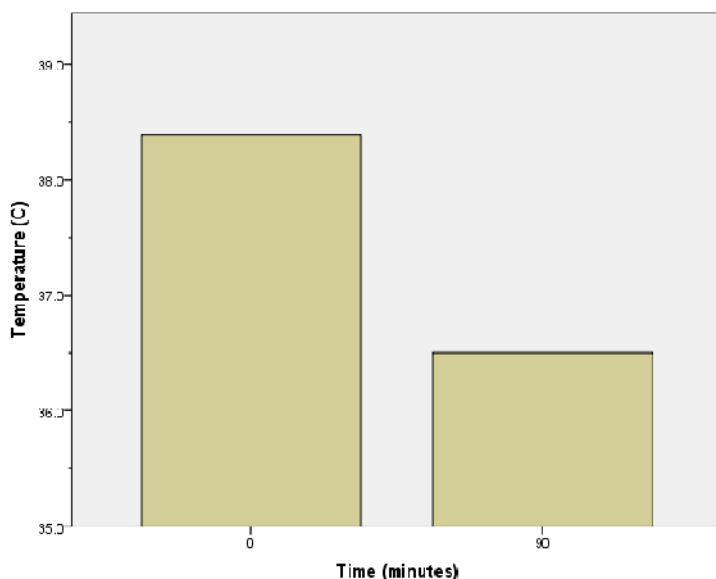


Figure 2. Temperature Profile of an 80-year-old Male Patient Provided Antipyretics via Catheter. [Please click here to view a larger version of this figure.](#)

Catheter Part	Description	Purpose
Medication Administration Port	Clear Plastic Port Marked "MEDS"	Connects with an enteral/oral syringe to deliver medications and liquids to the rectum
Balloon Inflation Port	Red Plastic Port Marked "Inflate w 15 mL"	Connects with Luer type syringe to inflate balloon with 15 mL water
Placement Marker Lines	Two black arrow markers between black line towards the tip of the catheter	Assists in proper placement of the catheter in the distal 1/3 of the rectum
Balloon	Inflatable balloon towards the tip of the catheter	Holds the medication and device in the rectum and is easily expelled by defecation.
Medication Delivery Holes	Four holes near the tip of the catheter	Allow for transmission of medications and fluids from the catheter to the rectum.

Table 1: Catheter - Parts/Description/Purpose.

Discussion

The administration of medications and fluids via rectal mucosal absorption has been utilized in various environments over a long time period, with the provision of fluids by this route specifically given the term proctoclysis or rectoclysis⁶⁻⁹. Nevertheless, despite the effectiveness of this route, practical use has been limited by the availability of a convenient, and easy-to-use device to leverage it. The initial reports of use in the ED have shown that the catheter is easy to place, and the onset of effects from medications administered via the catheter appears quickly. Since the time to place the device is minimal, the catheter appears to be a valuable medications and fluids administration device in emergency and critical care settings.

Because the device is non-sterile, and is placed in the rectum in a similar fashion to a standard Foley catheter placed in the urethra, minimal skill is required, and almost no advanced training is necessary. The most critical component in rectal delivery of medication is an understanding of dosing via the rectal route. Most opiates, benzodiazepines, and NSAIDs are well absorbed and dosing is comparable to the oral route. An extensive review of the literature on rectal absorption of medications used in the palliative setting has been compiled¹⁵. It is important to note that hypotonic fluids should be used for proctoclysis, as absorption through the rectal mucosa occurs by passive diffusion and isotonic and hypertonic fluids may have a cathartic effect. With the use of hypotonic fluids, rectal hydration via infusing water at a rate of up to 400 mL/h has been demonstrated, with a mean rate of 224 mL/h⁷.

Due to the simplicity of the device there is minimal need for troubleshooting. It is important to note that the medication port on the catheter mates only with an enteral syringe. Luer syringes cannot connect to the medication port. This feature was designed to avoid misconnection errors between parenteral devices (Luer syringe) and gastrointestinal device (enteral syringe). For this reason, an IV bag cannot be attached directly to the catheter for administration of fluids as IV tubing is fitted with Luer connectors. A "Luer to Enteral" adaptor can be purchased for this purpose, or hydration can be performed by bolusing the patient with fluids using a 60 mL enteral syringe that comes with the catheter in the kit supplied by the manufacturer.

Critical situations such as shock, sepsis or cardiac arrest need parenteral access either by IV or intraosseous methods, as rectal medication and fluid administration does not provide immediate absorption; however, a rectal catheter can provide an additional rapidly accessible route in these situations. For example, in the incidence of sepsis, when protocols demand large volumes of fluids in a short period of time, multiple IV access points are necessary, and rectal fluid delivery can be a way to increase vascular volume rapidly while multiple IVs are being implemented. In addition, the catheter can provide a route of access for medications that cannot be instilled intravenously, such as Buspirone for the control of shivering in hypothermia induction and aspirin for platelet inhibition and fever reduction.

Difficult IV access is an increasingly common problem in the ED setting. Fields *et al.* found that 1 in 10 patients admitted into an urban ED were considered to be 'difficult IV access'¹⁶. For patients in whom vascular access is difficult, delayed or unnecessary, this new method of medication and fluid delivery may prove invaluable in the ED. Medications and fluids can be administered in minutes while awaiting ultrasound placement, central venous placement, or during repeated attempts at peripheral placement. In these cases, the rectal catheter can allow for hydration or management of a patient's condition that may be complicating IV access, by decreasing the difficulty of placement. In pediatric patients, who are well known to have difficult IV access (and generally fear invasive or painful procedures), this technique may be a good alternative.

Intraosseous infusion is painful and pre-medication with lidocaine can be time consuming. For alert patients that are not critically ill, the use of this catheter may be preferable from a cost, time, and patient comfort perspective, since the cost of the device offers significant savings over alternatives such as a popular intraosseous needle delivery system in widespread use. The catheter may be a good alternative to nasogastric placement for fluid and medication therapy since no imaging, such as X-ray confirmation of placement, is necessary and it is less likely to cause discomfort or injury during placement. Even with ultrasound guidance technology, IV placement can be significantly delayed and treatment can be initiated and even completed without IV access offering additional savings in time and money. Significant savings can be realized in the use of lower cost oral medications (such as tablets that can be crushed and administered via the catheter) compared to intravenous formulations of the same medication. Finally, this device has less potential for complications compared to IV access, decreasing the incidence of infections, infiltration, and embolism associated with intravenous treatment.

Patient types that commonly present as difficult peripheral IV access and may benefit from this method include patients with diabetes, obesity, renal failure, edema, IV drug use or those receiving chemotherapy. Most pediatric and elderly patients may also benefit. Specific clinical needs for which the catheter may be used in the emergency setting may include hydration, fever, pain, agitation, seizures, migraine, sickle cell crisis, gastroparesis or nausea and vomiting.

The catheter can also be used for instillation of retention enemas such as lactulose for elevated ammonia, Kayexalate for elevated potassium, and saline or other preparations for severe constipation, or to assist for disimpaction. It is an alternative option for retention enemas than the currently utilized bowel management systems which employ a larger diameter shaft and balloon, and it is easier to insert and use.

There are several other benefits of using of the catheter in the ED setting, including decreased wait times, decreased staff burden, and decreased iatrogenic complications related to intravenous therapy. Patient satisfaction can be improved with reduced wait times, and patient symptoms such as pain or vomiting could be relieved quickly without having to wait for IV access.

Disclosures

The authors have nothing to disclose.

Acknowledgements

The authors acknowledge the support of the Departments of Emergency Medicine and Pharmacy at the Advocate Christ Medical Center.

References

1. Chiang, L. M. *et al.* Rectal diazepam solution is as good as rectal administration of intravenous diazepam in the first-aid cessation of seizures in children with intractable epilepsy. *Pediatr Neonatol.* **52** (1), 30-33 (2011).
2. Pasero, C. Perioperative rectal administration of nonopioid analgesics. *J Perianesth Nurs.* **25** (1), 5-6 (2010).
3. Fouad, E. A. *et al.* Preparation and investigation of acetyl salicylic acid-caffeine complex for rectal administration. *Pharm Dev Technol.* **15** (3), 249-257 (2010).
4. Zweig, S. B., Schlosser, J. R., Thomas, S. A., Levy, C. J., & Fleckman, A. M. Rectal administration of propylthiouracil in suppository form in patients with thyrotoxicosis and critical illness: case report and review of literature. *Endocr Pract.* **12** (1), 43-47 (2006).
5. Nabil, N., Miner, D. J., & Amatruda, J. M. Methimazole: an alternative route of administration. *J Clin Endocrinol Metab.* **54** (1), 180-181 (1982).
6. Needham, D. Proctoclysis for hydration. *Lancet.* **345** (8949), 596 (1995).
7. Bruera, E., Schoeller, T., & Pruvost, M. Proctoclysis for hydration of terminal cancer patients. *Lancet.* **344** (8938), 1699 (1994).
8. Trout, H. H. Proctoclysis: Some clinical and experimental observations. *Journal of the American Medical Association.* **LVIII** (18), 1352-1354 (1912).
9. Murphy, J. B. Proctoclysis in the treatment of peritonitis. *Journal of the American Medical Association.* **LII** (16), 1248-1250 (1909).
10. Tremayne, V. Emergency rectal infusion of fluid in rural or remote settings. *Emerg Nurse.* **17** (9), 26-28 (2010).
11. Lam, Y. W., Lam, A., & Macy, B. Pharmacokinetics of Phenobarbital in Microenema Via Macy Catheter Versus Suppository. *J Pain Symptom Manage.* (2016).
12. de Boer, A. G., Moolenaar, F., de Leede, L. G., & Breimer, D. D. Rectal drug administration: clinical pharmacokinetic considerations. *Clin Pharmacokinet.* **7** (4), 285-311 (1982).
13. Honasoge, A., Parker, B., Wesselhoff, K., Lyons, N., & Kulstad, E. First Use of a New Device for Administration of Buspirone and Acetaminophen to Suppress Shivering During Therapeutic Hypothermia. *Ther Hypothermia Temp Manag.* (2016).
14. Lyons, N. *et al.* An alternative for rapid administration of medication and fluids in the emergency setting using a novel device. *Am J Emerg Med.* **33** (8), 1113 e1115-1116 (2015).
15. Davis, M. P., Walsh, D., LeGrand, S. B., & Naughton, M. Symptom control in cancer patients: the clinical pharmacology and therapeutic role of suppositories and rectal suspensions. *Support Care Cancer.* **10** (2), 117-138 (2002).
16. Fields, J. M., Piela, N. E., Au, A. K., & Ku, B. S. Risk factors associated with difficult venous access in adult ED patients. *Am J Emerg Med.* **32** (10), 1179-1182 (2014).